

Economic Value of Systems and Services

**We Lay the Foundation for Successful Patient Access and Reimbursement by
Continuously Demonstrating the Value of Our Systems and Services**



NBI

The Power of Accurate Diagnosis



Benefits

No Additional Costs,
No Extra Equipment,
Disposables or Drugs
Needed

High Versatility — Proven
and trusted across Multi-
ple Medical Disciplines

Easy Handling —
Switching Modes at the
Push of a Button

- NBI (Narrow Band Imaging) facilitates early detection, and can **improve patient therapy and its outcomes leading to reduced treatment costs.**⁵
- It is **trusted for multiple medical disciplines** (like gastroenterology, urology, ENT), and in different procedural stages for rigid and flexible endoscopy.
- Olympus medical imaging systems, camera heads and videoscopes* come with **NBI as standard.**
- NBI may **enhance patient outcome** through increased detection of, for example, laryngeal cancer¹ or diminutive polyps⁶, as well as a **reduction in recurrence due to early diagnosis.**⁴
- The technology is clinically proven and **recommended by various societies.**^{**}
- NBI optical diagnosis training is widely available, helping you to advance patient care.

*Applicable to EXERA II, LUCERA SPECTRUM, VISERA from 2006 onwards.
**European Laryngological Society¹⁻³, European/American Society for Gastrointestinal Endoscopy^{9,10}.

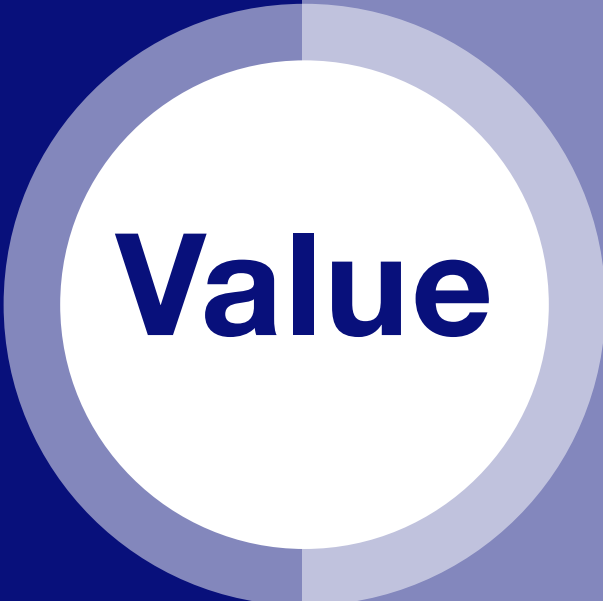Value Dimensions

NBI Provides a Number of Values for You and Your Staff

Economics

Cost and Cash Flow Management

- Substantially contributes to reduced costs of colonoscopy.⁸
- Standard technology in Olympus medical imaging systems without extra cost for purchase.



Efficiency

Process and Workflow Management

- Finds more lesions with the push of a button.
- Eliminates unnecessary biopsies for histopathology testing.^{7,8}
- Enables direct patient feedback.*

*Thanks to real-time distinction of benign/malign lesions

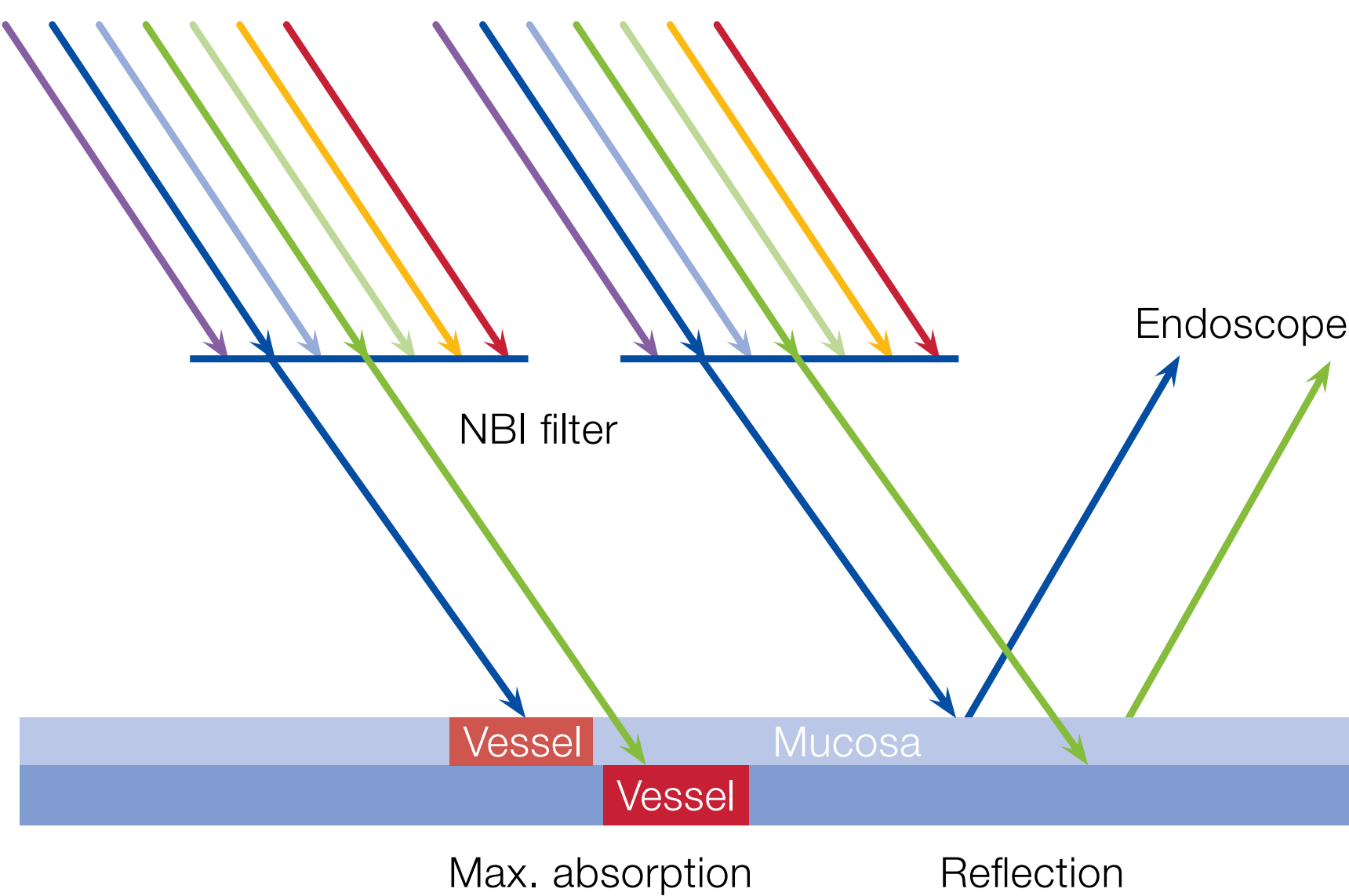
NBI

The Power of Accurate Diagnosis

How NBI Works

NBI is an optical technology which helps to visualize the minutest vascular and mucosal patterns. It uses only wavelengths absorbed by hemoglobin for maximum contrast. Compared to white-light endoscopy (WLE), the images of capillaries are less blurred and the probability of missing a lesion is reduced.

NBI only uses two specific wavelengths. These two wavelengths of blue and green light hit the surface of the tissue, and the light is highly absorbed by hemoglobin in the blood vessels. While the blue light is absorbed by the capillaries in the mucosa, the green light reaches deeper to the submucosal area, where it is reflected by the blood vessels. Therefore, NBI creates a significantly higher contrast between blood vessels and the surrounding tissue in contrast to WLE.



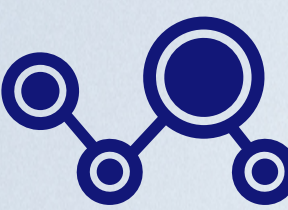
Absorption of narrow band light by capillaries on the mucosal surface (blue) and veins in the submucosa (green)

NBI Helps to Reduce Total Cost of Ownership

The versatility and usability of NBI in a wide range of specialties eliminates the need to invest in additional capital equipment and reduces total cost of ownership.*



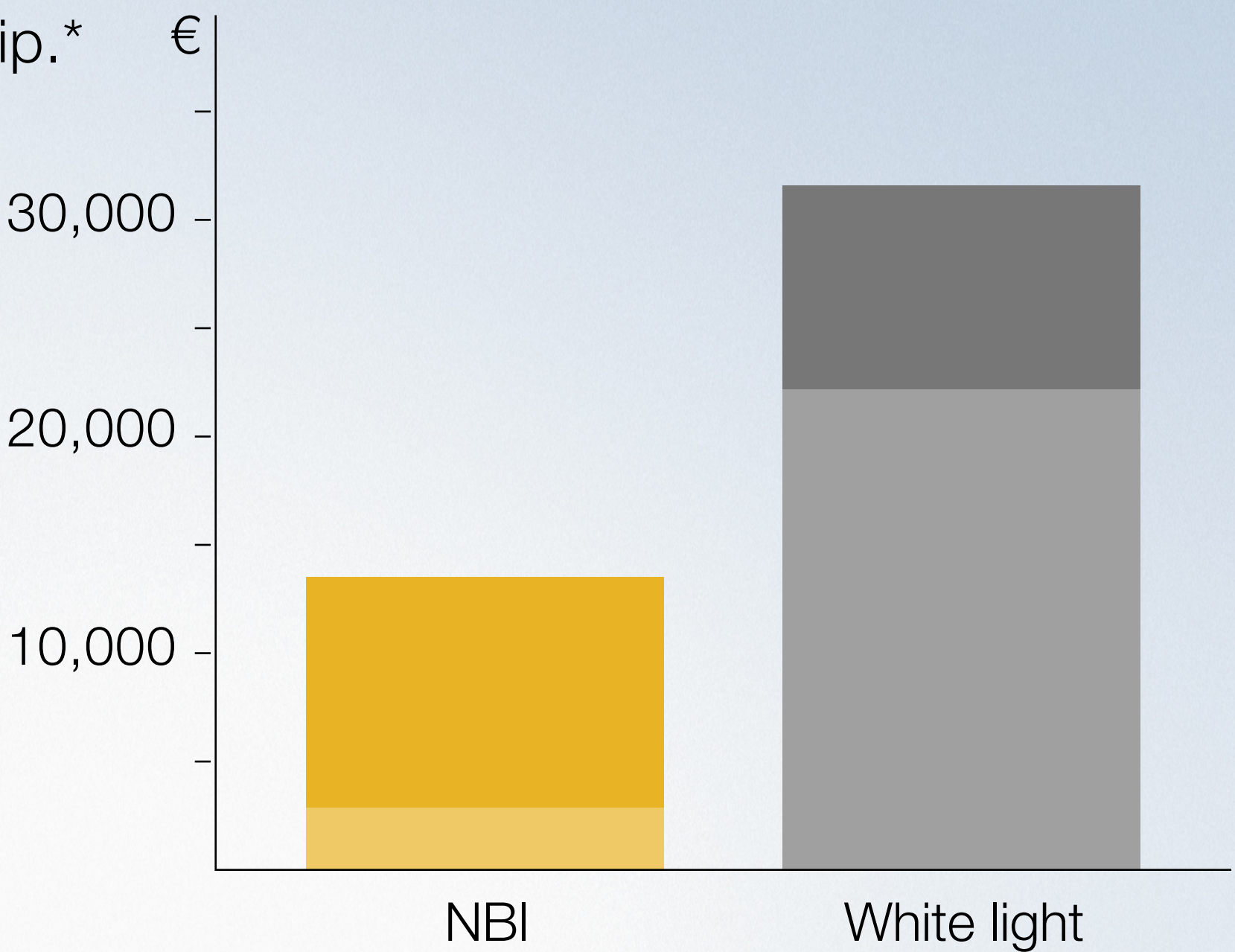
NBI comes at no additional cost for extra equipment, disposables or drugs



Can be used for various specialties like general surgery, urology, GYN, ENT

- Cost of equipment and service
- Recurrence

Total Cost per Year
(Example Based on 50 Patients)



*When compared to conventional white-light endoscopy system without NBI ("white light").

References

- ¹ Simo, R., Bradley, P., Chevalier, D., Dikkers, F., Eckel, H., Matar, N., Peretti, G., Piazza, C., Remacle, M., & Quer, M. (2014). European Laryngological Society: ELS recommendations for the follow-up of patients treated for laryngeal cancer. *European archives of oto-rhino-laryngology : official journal of the European Federation of Oto-Rhino-Laryngological Societies (EUROS)* : affiliated with the German Society for Oto-Rhino-Laryngology - Head and Neck Surgery, 271(9), 2469–2479. <https://doi.org/10.1007/s00405-014-2966-x>.
- ² Kraft, M., Fostiropoulos, K., Gürtler, N., Arnoux, A., Davaris, N., & Arens, C. (2016). Value of narrow band imaging in the early diagnosis of laryngeal cancer. *Head & neck*, 38(1), 15–20. <https://doi.org/10.1002/hed.23838>.
- ³ Garofolo, S., Piazza, C., Del Bon, F., Mangili, S., Guastini, L., Mora, F., Nicolai, P., & Peretti, G. (2015). Intraoperative narrow band imaging better delineates superficial resection margins during transoral laser microsurgery for early glottic cancer. *The Annals of otology, rhinology, and laryngology*, 124(4), 294–298. <https://doi.org/10.1177/0003489414556082>.
- ⁴ Plaat, B., Zwakenberg, M. A., van Zwol, J. G., Wedman, J., van der Laan, B., Halmos, G. B., & Dikkers, F. G. (2017). Narrow-band imaging in transoral laser surgery for early glottic cancer in relation to clinical outcome. *Head & neck*, 39(7), 1343–1348. <https://doi.org/10.1002/hed.24773>.
- ⁵ Kang, W., Cui, Z., Chen, Q., Zhang, D., Zhang, H., & Jin, X. (2017). Narrow band imaging-assisted transurethral resection reduces the recurrence risk of non-muscle invasive bladder cancer: A systematic review and meta-analysis. *Oncotarget*, 8(14), 23880–23890. <https://doi.org/10.18632/oncotarget.13054>.
- ⁶ Leung, J. W., Mann, S. K., Siao-Salera, R., Ransibrahmanakul, K., Lim, B., Cabrera, H., Canete, W., Barredo, P., Gutierrez, R., & Leung, F. W. (2009). A randomized, controlled comparison of warm water infusion in lieu of air insufflation versus air insufflation for aiding colonoscopy insertion in sedated patients undergoing colorectal cancer screening and surveillance. *Gastrointestinal endoscopy*, 70(3), 505–510. <https://doi.org/10.1016/j.gie.2008.12.253>.
- ⁷ Ignjatovic, A., East, J. E., Suzuki, N., Vance, M., Guenther, T., & Saunders, B. P. (2009). Optical diagnosis of small colorectal polyps at routine colonoscopy (Detect InSpect ChAracterise Resect and Discard; DISCARD trial): a prospective cohort study. *The Lancet. Oncology*, 10(12), 1171–1178. [https://doi.org/10.1016/S1470-2045\(09\)70329-8](https://doi.org/10.1016/S1470-2045(09)70329-8).
- ⁸ Solon, C., Klausnitzer, R., Blissett, D., & Ihara, Z. (2016). Economic value of narrow band imaging versus white light endoscopy for the characterization of diminutive polyps in the colon: systematic literature review and cost-consequence model. *Journal of medical economics*, 19(11), 1040–1048. <https://doi.org/10.1080/13696998.2016.1192550>.
- ⁹ Kamiński, M. F., Hassan, C., Bisschops, R., Pohl, J., Pellisé, M., Dekker, E., Ignjatovic-Wilson, A., Hoffman, A., Longcroft-Wheaton, G., Heresbach, D., Dumonceau, J. M., & East, J. E. (2014). Advanced imaging for detection and differentiation of colorectal neoplasia: European Society of Gastrointestinal Endoscopy (ESGE) Guideline. *Endoscopy*, 46(5), 435–449. <https://doi.org/10.1055/s-0034-1365348>.
- ¹⁰ ASGE Technology Committee, Abu Dayyeh, B. K., Thosani, N., Konda, V., Wallace, M. B., Rex, D. K., Chauhan, S. S., Hwang, J. H., Komanduri, S., Manfredi, M., Maple, J. T., Murad, F. M., Siddiqui, U. D., & Banerjee, S. (2015). ASGE Technology Committee systematic review and meta-analysis assessing the ASGE PIV thresholds for adopting real-time endoscopic assessment of the histology of diminutive colorectal polyps. *Gastrointestinal endoscopy*, 81(3), 502.e1–502.e16. <https://doi.org/10.1016/j.gie.2014.12.022>.

Read More About ...

As medical knowledge is constantly growing, technical modifications or changes of the product design, product specifications, accessories and service offerings may be required.

OLYMPUS

OLYMPUS EUROPA SE & CO. KG

Postbox 10 49 08, 20034 Hamburg, Germany

Wendenstrasse 20, 20097 Hamburg, Germany

Phone: +49 40 23773-0, Fax: +49 40 233765

www.olympus-europa.com