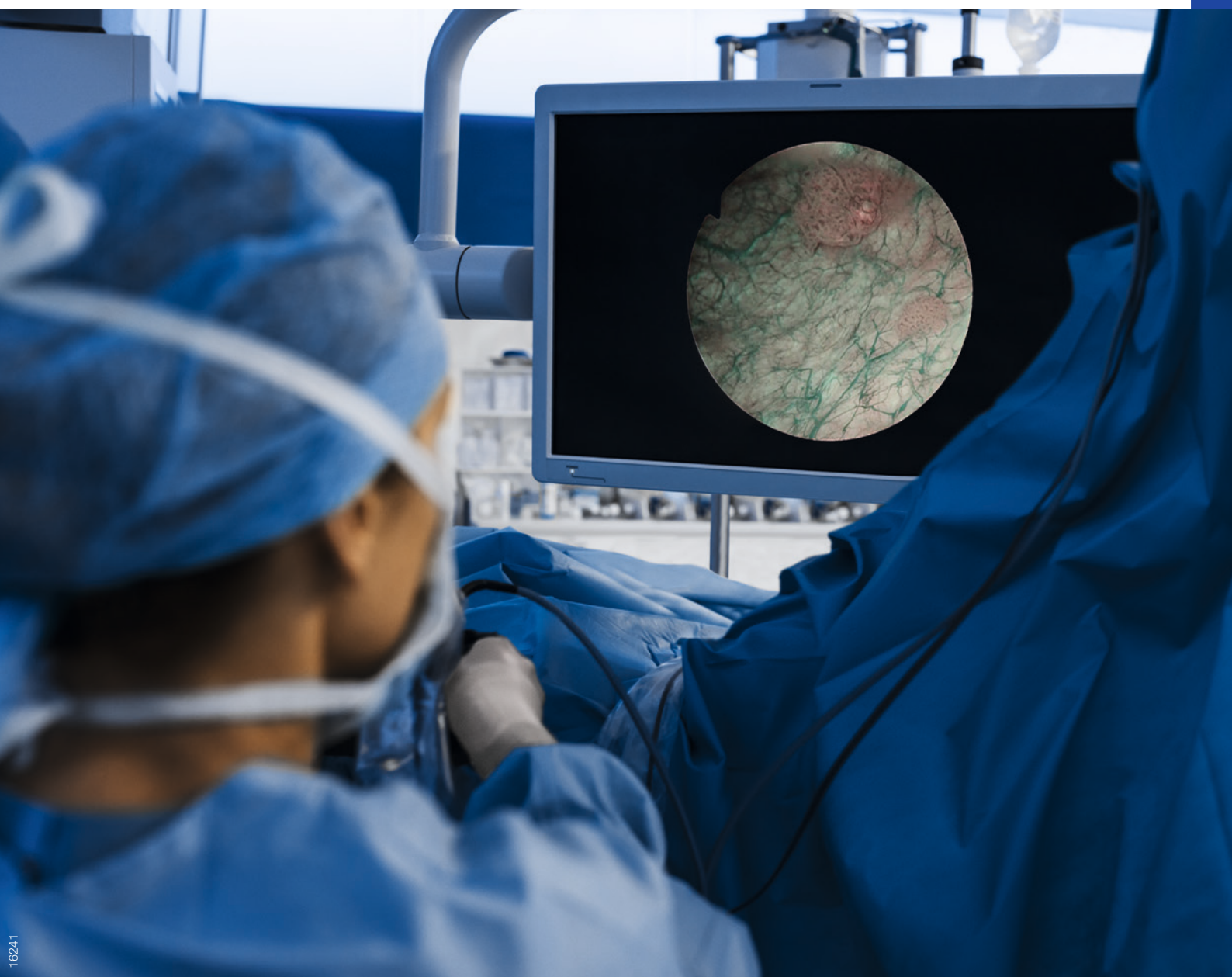


INCREASE DETECTION, REDUCE RECURRENCE

NBI Is Clinically Proven to Diagnose More Bladder Cancer



NBI – PROVEN FOR BETTER CLINICAL OUTCOMES

Narrow Band Imaging (NBI) opens new therapeutic and diagnostic possibilities that support and improve a urologist's ability to provide an early precise optical diagnosis of bladder tumors, such as non-muscle invasive bladder cancer (NMIBC). About 50–70% of patients suffer from recurrent superficial bladder tumors after their initial treatment¹. Small papillary tumors, or carcinoma in situ (CIS), are missed at an estimated rate of 10 to 20%².

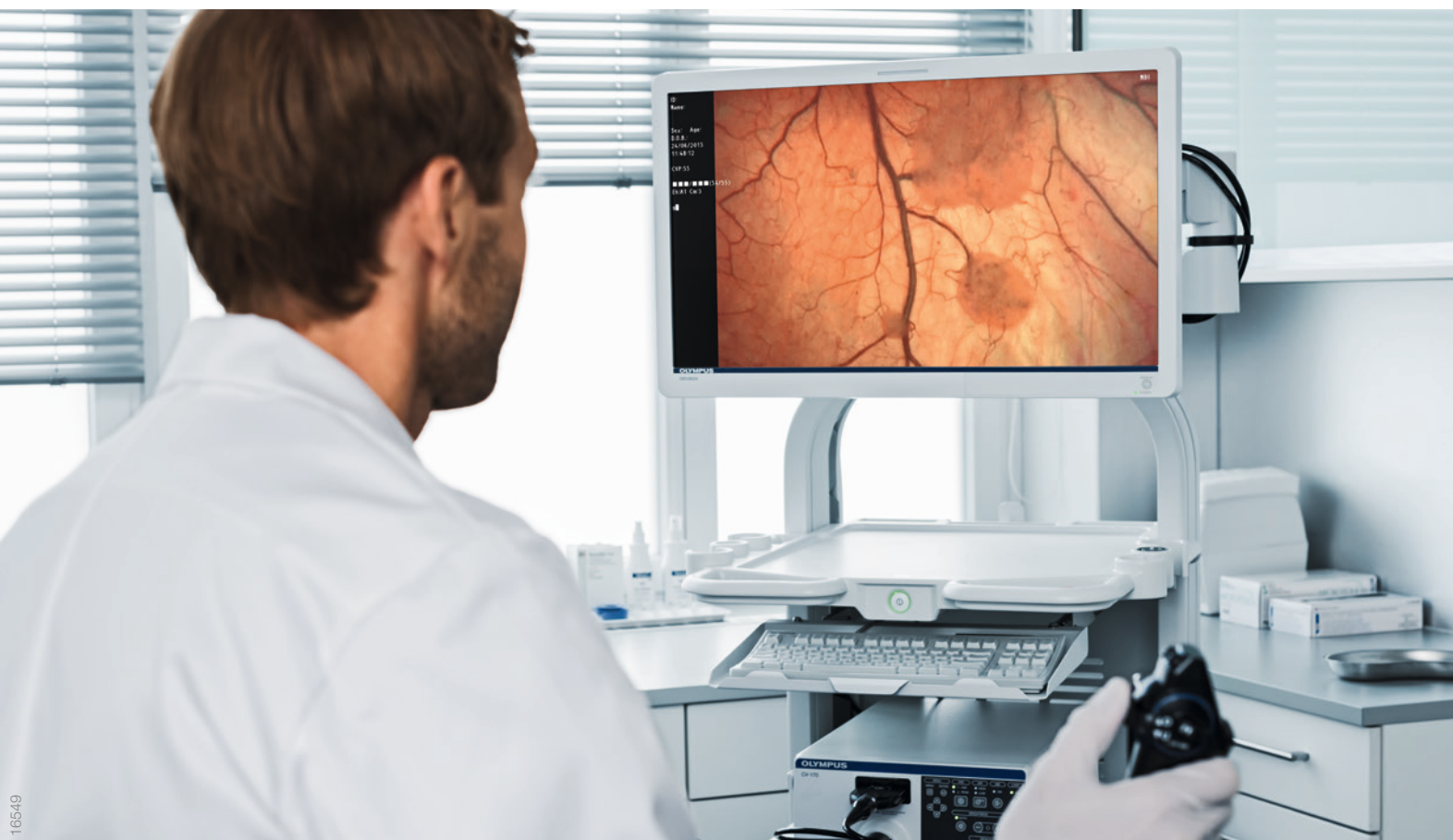NBI is a patented and unique optical filter technology that greatly enhances the visibility of vascular and mucosal structures in the bladder using only those wavelengths highly absorbed by hemoglobin. That is why NBI achieves maximum contrast, thus revealing significantly more details of the examined tissue than white-light imaging (WLI) cystoscopy.

It has been clinically proven that by using NBI during procedures, more superficial tumors of the bladder mucosa are diagnosed than when using WLI. That ultimately leads to reduced recurrence rates³.

INCREASE DETECTION, REDUCE RECURRENCE

A better view of superficial structures provides urologists with the strongest impact on improving the detection rate of superficial bladder tumors.

With NBI, it is simply easier to identify the malign structures of NMIBC and other small tumors. This has a direct impact on patient outcomes: Compared to WLI, NBI visualizes 28% more CIS⁴, and detects bladder cancer in 17% additional patients⁴. Furthermore, NBI reduces the risk of recurrence to 17% at one year³.



28%

NBI Visualizes 28% More Carcinomas in Situ Compared to WLI⁴



17%

NBI Detects Bladder Cancer in 17% Additional Patients Compared to WLI⁴



17%

NBI Reduces the Risk of Recurrence to 17% at One Year³

More information about the clinical evidence of NBI: www.nbi-portal.eu/clinicallyproven



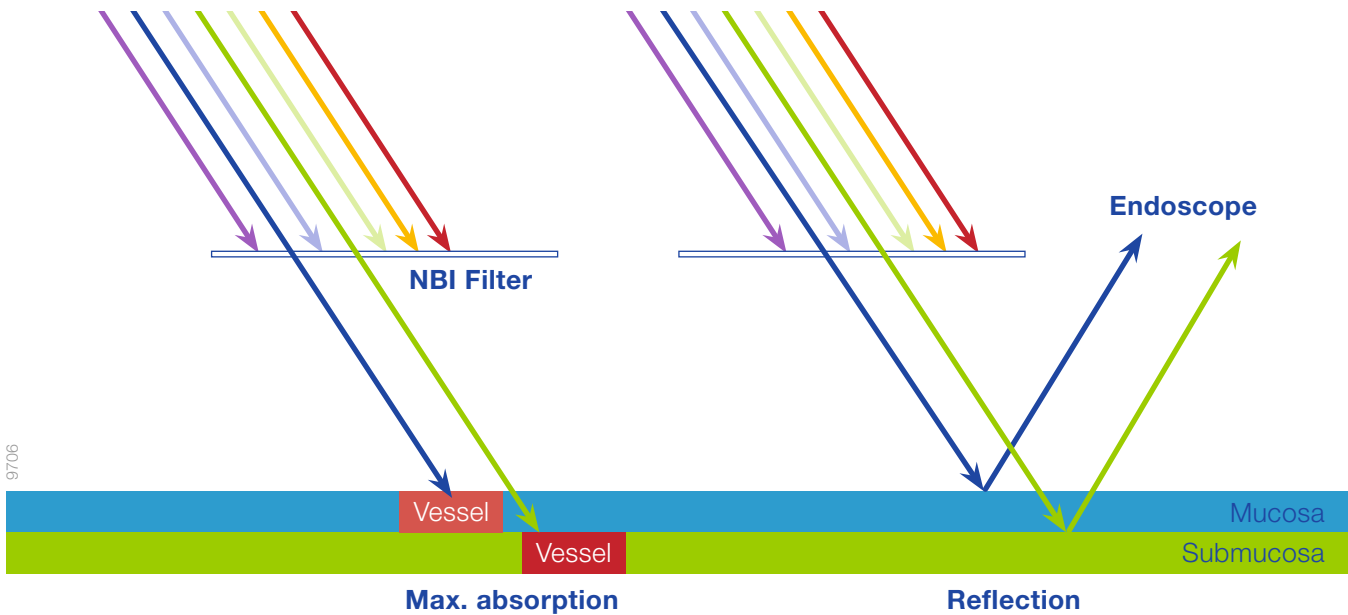
Practical Benefits

- Available at a push of a button
- No preparation time needed
- No additional procedure costs

NBI – THE UNDERLYING PRINCIPLE

NBI is a patented optical filter technology for diagnosing and treating NMIBC that creates a significantly higher contrast between blood vessels and the surrounding tissue than WLI. NBI clearly sets a new standard in endoscopy and bladder cancer management.

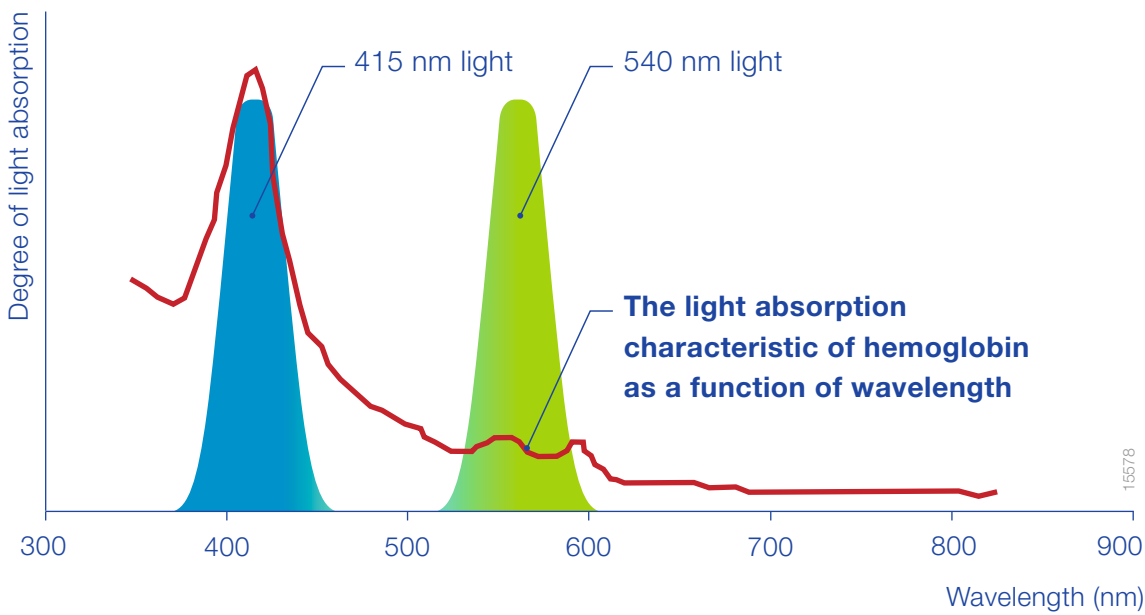
The way NBI works is easy to understand. WLI contains all colors. When WLI hits the surface of a tissue, all colors are absorbed. NBI uses only blue and green light. When blue and green light hit the surface of the tissue, it is highly absorbed by hemoglobin in the blood vessels. The blue and green light of NBI penetrates differently into the tissue layers.



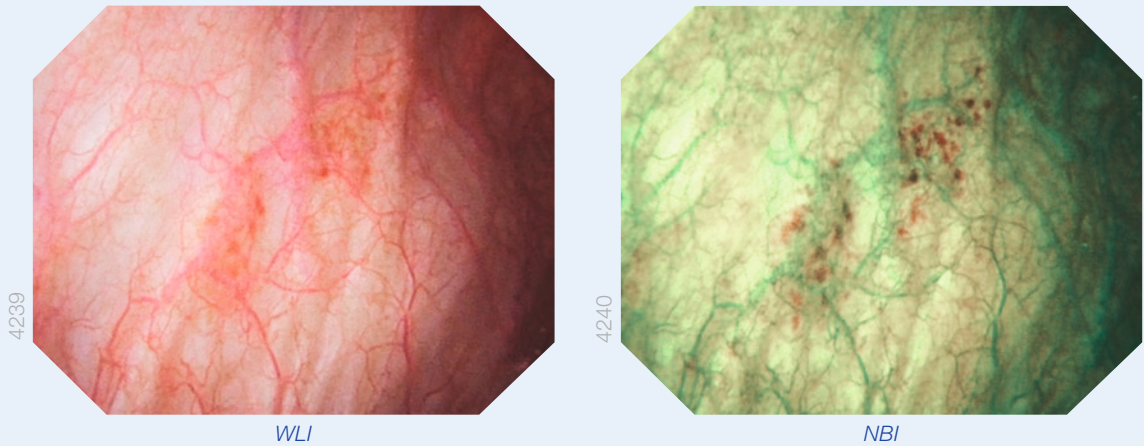
NBI light is absorbed by capillaries on the mucosal surface (blue) and veins in the submucosa (green).

While blue light is absorbed by the capillaries in the mucosa, green light reaches deeper to the submucosal area, where it is reflected by the blood vessels. This is why NBI creates a significantly higher contrast between blood vessels and the surrounding tissue than WLI.

The degree of light absorption of hemoglobin depends on the wavelength. Blue light with a wavelength of 415 nm and green light with a wavelength of 540 nm are highly absorbed by hemoglobin in the blood vessels. Since small tumors are often surrounded by a large number of blood vessels, NBI helps to detect them at an early stage and to analyze these areas accordingly. Thus, NBI supports the early diagnosis of NMIBC.



The amount of light hemoglobin absorbs depends on its wavelength.



NBI – The Main Practical Benefits

- NBI is a patented filter technology that uses only blue and green light, thus creating a significantly higher contrast between blood vessels and the surrounding tissue than WLI.
- Because NBI is a purely optical system, it does not need any installation and therefore no time-consuming preparation time.
- NBI is available with every Olympus Imaging System at a push of a button and therefore generates no additional procedure costs.

NBI – THE SCIENTIFIC EVALUATION

NBI in International Guidelines

Numerous international specialist associations and institutes such as EAU, NICE, and AUA have commented on the use of NBI for the diagnosis and therapy of NMIBC in their guidelines.

NBI is Clinically Proven

A growing number of studies show that optical diagnosis with NBI improves lesion detection in the bladder, resulting in several clinical advantages for patient care. The different study outcomes are presented below.

“ In narrow-band imaging (NBI), the contrast between normal urothelium and hyper-vascular cancer tissue is enhanced. Initial studies have demonstrated improved cancer detection by NBI-guided biopsies and resection. ”

European Association of Urology (EAU)⁵

“ For diagnosing and staging bladder cancer, the guidelines recommend offering white-light-guided TUR-BT with one of photodynamic diagnosis, narrow-band imaging ... to people with suspected bladder cancer. ”

National Institute for Health and Care Excellence (NICE)⁶

“ In a patient with NMIBC, a clinician may consider use of NBI to increase detection and decrease recurrence. Furthermore, enhanced cystoscopic techniques, including blue light cystoscopy (BLC) and narrow-band imaging (NBI), seem particularly valuable for diagnosis of urothelial carcinoma in the setting of positive cytology but negative white light cystoscopy (WLC). ”

American Urological Association (AUA)⁷



28%
NBI Visualizes 28% More Carcinomas in Situ Compared to WLI⁴



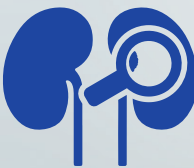17%
NBI Detects Bladder Cancer in 17% Additional Patients Compared to WLI⁴



17%
NBI Reduces the Risk of Recurrence to 17% at One Year³



NBI PDD
Using NBI or PDD during TUR-BT Reduces Recurrence Rate Compared to WLI ⁸



23%
NBI Increases Detection Rate of UUT-TCC by 23% Compared to WLI⁹

Explore the relevant studies about NBI in more detail from page 16 on.

NBI – FOR VARIOUS ENDOUROLOGICAL PROCEDURES

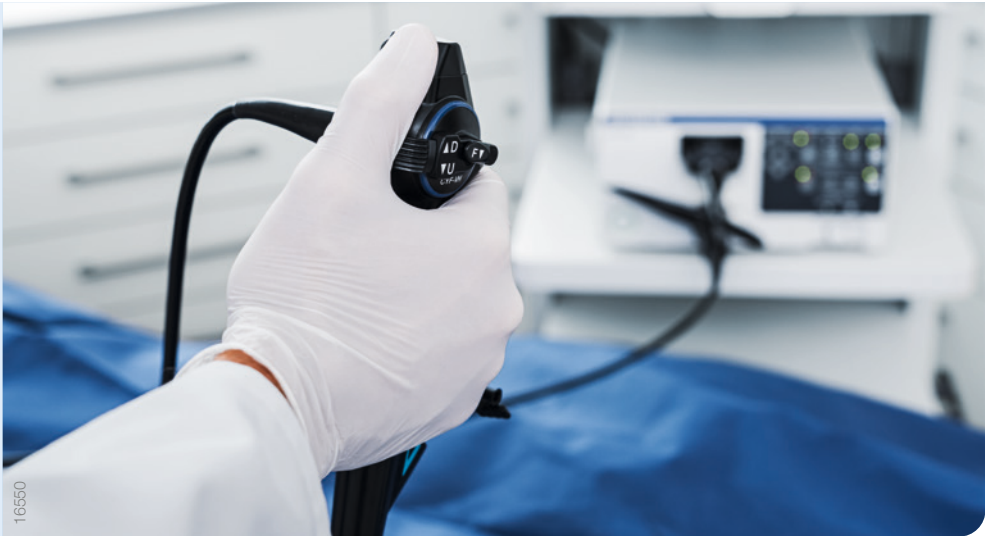NBI opens possibilities that support and improve the ability to provide an early precise diagnosis of bladder and upper urinary tract tumors.

Flexible Cystoscopy

Flexible cystoscopy either for early diagnosis or follow-up procedures can be performed using NBI in the outpatient setting. It is clinically proven that NBI diagnoses more bladder cancer compared to WLI.

Related Products

- **CV-170**
Imaging system
- **CYF-VH**
Flexible video cystoscope



Flexible Ureteroscopy

Flexible ureteroscopy for urinary tract tumor visualization can be performed using NBI in the operating room. It is clinically proven that NBI improves the UUT-TCC detection rate compared to WLI.

Related Products

- **VISERA ELITE II**
Imaging system
- **URF-V2**
Flexible video ureteroscope



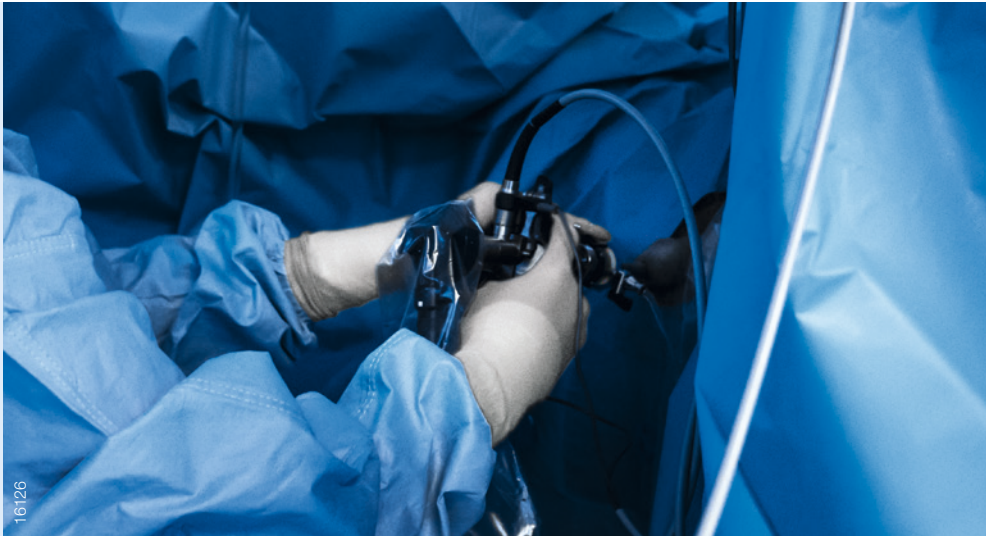When using NBI while performing transurethral resection of bladder tumor (TUR-BT), diagnosis and PLASMA therapy of NMIBC can be done simultaneously. The combination of the two technologies – NBI and PLASMA during TUR-BT – leads to an optimal clinical outcome.

TUR-BT

NBI and PLASMA can be used to diagnose and treat NMIBC. With NBI, lesion limits can be visualized better. This allows in the first step precise marking, as well as even the complete resection of the bladder tumor using the PLASMA technology.

Related Products

- **VISERA ELITE II**
Imaging system
- **OES Pro**
Resectoscope
- **PLASMA Electrodes**
Various procedure-specific electrodes for conventional and en bloc resection



“With NBI I can make a safer diagnosis, I can simply see better what the patient has.”

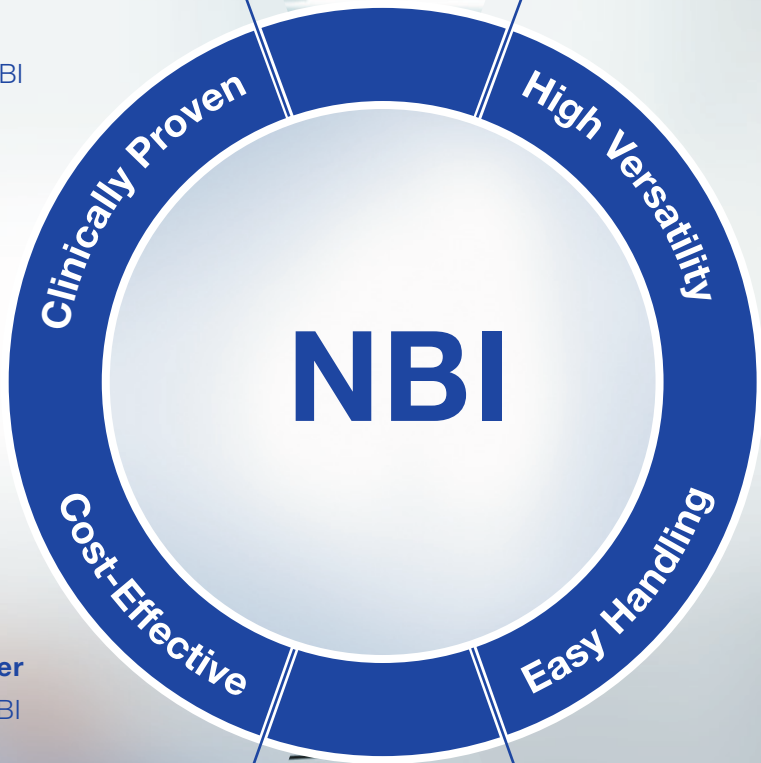
Prof. Jørgen Bjerggaard Jensen
Department of Urology at Aarhus University Hospital
Chairman of the Danish Bladder Cancer Group

NBI – THE SAFE SOLUTION FOR EARLY NMIBC DETECTION

NBI allows urologists to diagnose and treat bladder cancer even more precisely and reliably. It is clinically proven that by using NBI, urologists detect more cancer lesions than by using WLI. In addition, NBI is easy to handle and cost-effective. Combining all this, NBI is a safe way to improve the clinical outcomes in patients with suspected bladder cancer.

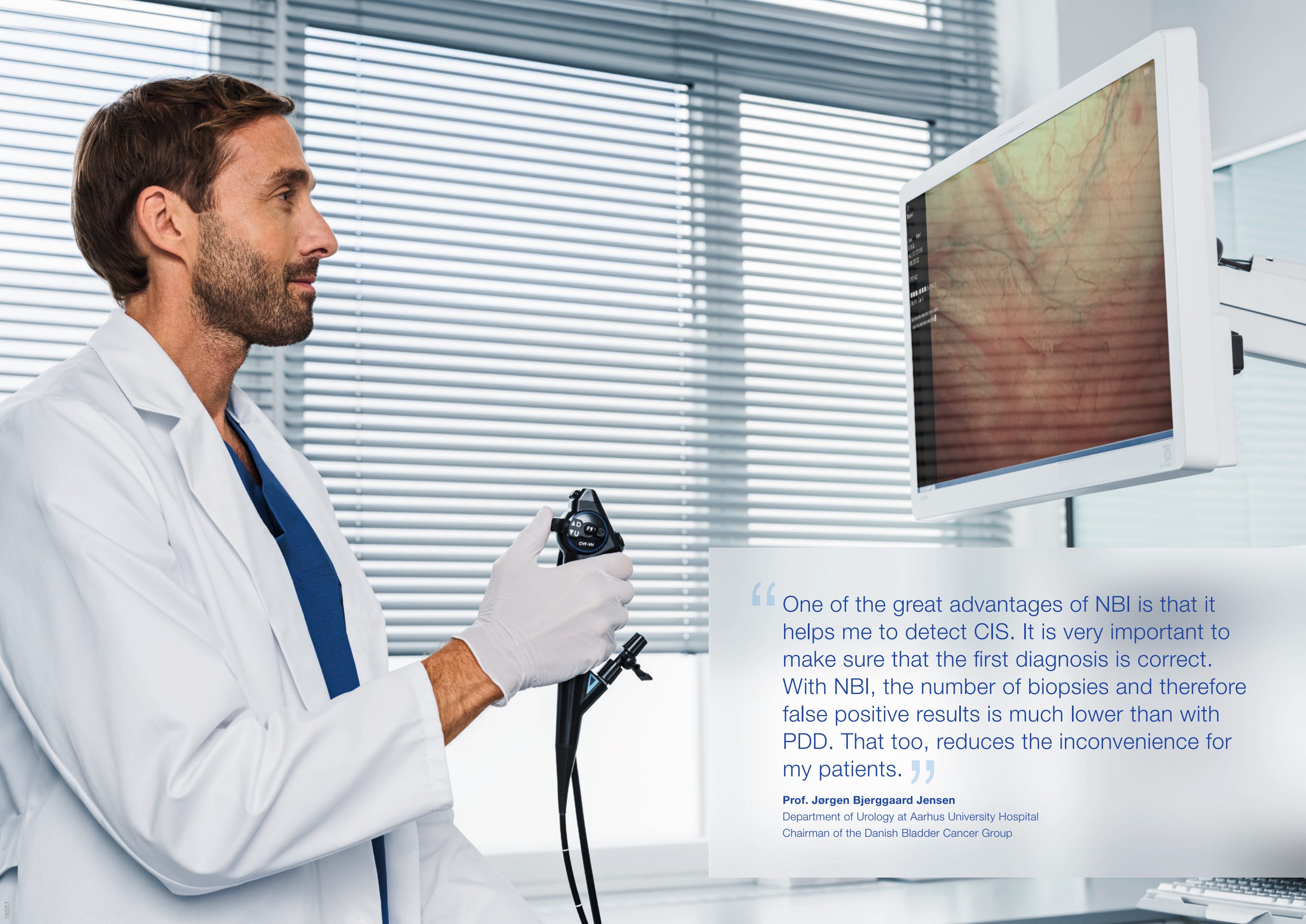Numerous studies, including a growing number of randomized clinical trials (RCTs) and meta-analyses, highlight the clinical value of NBI, especially with regard to the detection of bladder cancer and the recurrence risk. The results of these studies show that the use of NBI has several clinical benefits for patient outcome compared to WLI, while there are no contraindications for the use of NBI. NBI **detects NMIBC in 17% additional patients⁴**, **visualizes 28% more CIS⁴**, and increases the rate of UUT-TCC lesion detection in the kidney. Furthermore, it **reduces the risk of recurrence to 17%** at one year when used during a TUR-BT³.

There are no extra costs with NBI, as **no additional installations** or disposable items are required. Olympus Imaging Systems automatically feature NBI, so there is **no extra cost per procedure**. By improving the visibility of vascular and mucosal structures in the bladder, NBI supports and improves a urologist's ability to provide an early precise optical diagnosis of bladder tumors, which is likely to have positive cost effects.



NBI can be used during **various endourological procedures** such as TUR-BT, flexible cystoscopy, and flexible ureteroscopy. NBI is available for the Olympus VISERA ELITE II imaging system and combined with either OES Pro resectoscope or URF-V2 flexible video ureteroscope in the **operating room**, and with the Olympus CV-170 imaging system and the CYF-VH flexible video cystoscope for diagnostic examinations in **outpatient settings**.

Using NBI requires **no time-consuming preparation** or installation prior to performing procedures like flexible cystoscopy, flexible ureteroscopy, or TUR-BT. NBI is available for the latest Olympus Imaging Systems, and it can easily be switched on by a **push of a button**.



“ One of the great advantages of NBI is that it helps me to detect CIS. It is very important to make sure that the first diagnosis is correct. With NBI, the number of biopsies and therefore false positive results is much lower than with PDD. That too, reduces the inconvenience for my patients. ”

Prof. Jørgen Bjerggaard Jensen

Department of Urology at Aarhus University Hospital
Chairman of the Danish Bladder Cancer Group

01

Diagnosis of narrow-band imaging in non-muscle-invasive bladder cancer: A systematic review and meta-analysis⁴

Kaiwen Li, Tianxin Lin, Xinxiang Fan, Yu Duan and Jian Huang

Objective

The objective was to evaluate the diagnostic accuracy of cystoscopy assisted by narrow-band imaging compared with white-light imaging for non-muscleinvasive bladder cancer.

Methods

An electronic database search of PubMed, Embase, the Cochrane Library, Ovid and Web of Science was carried out for all articles comparing narrow-band imaging with white-light imaging cystoscopy in the detection of non-muscle-invasive bladder cancer. The review process followed the guidelines of the Cochrane Collaboration.

Results

Seven studies with prospectively collected data including a total of 1040 patients were identified, and 611 patients with 1476 tumours were detected by biopsy.

In the patient- and tumour-level analysis, an additional 17 % of patients (95 % confidence interval, 10–25 %)

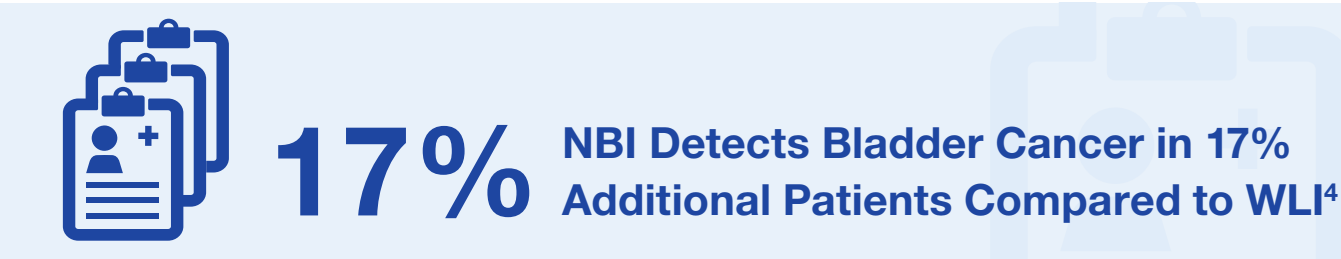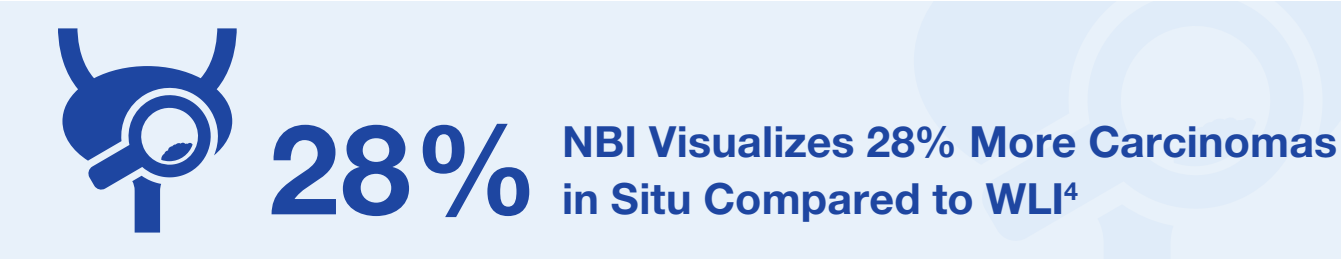and an additional 24 % of tumours (95 % confidence interval, 17–31 %) were detected by narrow-band imaging, respectively. In the patient- and tumour-level analysis, significantly higher detection rates using narrow-band imaging (rate difference 11 %; 95 % confidence interval 5–17 %; P < 0.001; and rate difference 19 %; 95 % confidence interval 12–26 %; P < 0.001, respectively) rather than white-light imaging were found. On the tumour level, an additional 28 % of carcinoma in situ was detected (95 % confidence interval 14–45 %) by narrow-band imaging, and a significantly higher detection rate (rate difference 11 %; 95 % confidence interval 1–21 %; P = 0.03) was found. The false-positive detection rate of tumour level did not differ significantly between the two techniques.

Conclusions

Cystoscopy assisted by narrow-band imaging detects more patients and tumors of non-muscle-invasive bladder cancer than white-light imaging, and it might be an additional or alternative diagnostic technique for non-muscle-invasive bladder cancer.

Key Outcomes⁴

- Cystoscopy assisted by NBI detects more NMIBC patients and tumors than WLI.
- NBI is an alternative diagnostic technique for NMIBC.
- In the patient- and tumor-level analyses, an additional 17% of patients and an additional 24% of tumors were detected by NBI compared to WLI.
- On the tumor level, an additional 28% of carcinomas in situ were detected by NBI compared to WLI, and a significantly higher detection rate was found.



02

Narrow band imaging-assisted transurethral resection reduces the recurrence risk of non-muscle invasive bladder cancer: A systematic review and meta-analysis³

Weiting Kang, Zilian Cui, Qianqian Chen, Dong Zhang, Haiyang Zhang and Xunbo Jin

Context

Compared with white light imaging (WLI) cystoscopy, narrow band imaging (NBI) cystoscopy could increase the visualization and detection of bladder cancer (BC) at the time of transurethral resection (TUR). NBI cystoscopy could increase the detection of BC, but it remains unclear whether narrow band imaging-assisted transurethral resection (NBI-TUR) could reduce the recurrence risk of non-muscle invasive bladder cancer (NMIBC). Several randomized clinical trials (RCTs) have recently tested the efficacy of NBI-TUR for NMIBC.

Objective

To perform a systematic review and meta-analysis of RCTs and evaluate the efficacy of NBI-TUR for NMIBC compared with white light imaging-assisted transurethral resection (WLI-TUR). The end point was recurrence risk.

Evidence Acquisition

A systematic review of PubMed, Medline, Ovid, Embase, Cochrane and Web of Science was performed in February 2016 and updated in July 2016.

Evidence Synthesis


Overall, six (n = 1084) of 278 trials were included. Three trials performed narrow band imaging-assisted electro-transurethral resection (NBI-ETUR), and two trials performed narrow band imaging-associated bipolar plasma vaporization (NBI-BPV). The last trial performed narrow band imaging-associated holmium laser resection (NBI-HLR). Statistical analysis was performed using Review Manager software (RevMan v.5.3; The Nordic Cochrane Center, Copenhagen, Denmark). The recurrence risk was compared by calculating risk ratios (RRs) with 95% confidence interval (CIs). Risk ratios with 95% CIs were calculated to compare 3-mo, 1-yr, and 2-yr survival rates. NBI-TUR was associated with improvements in the 3-mo recurrence risk (RR: 0.39; 95% CI, 0.26-0.60; p < 0.0001), 1-yr recurrence risk (RR: 0.52; 95% CI, 0.40-0.67; p < 0.00001) and 2-yr recurrence risk (RR: 0.60; 95% CI, 0.42-0.85; p = 0.004) compared with WLI-TUR.

Conclusions

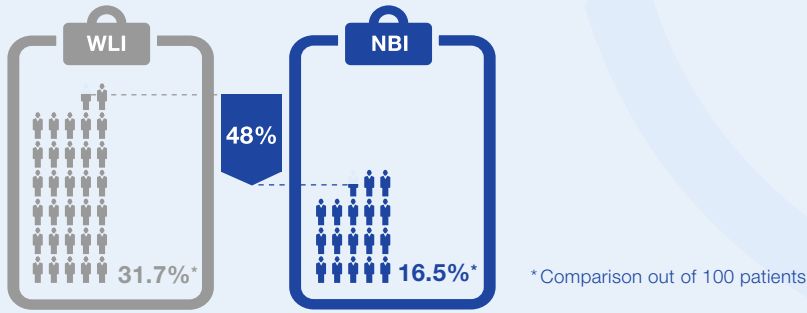
Compared with WLI-TUR, NBI-TUR can reduce the recurrence risk of NMIBC. The results of this review will facilitate the appropriate application of NBI in NMIBC.

Key Outcomes³

- Compared with WLI cystoscopy, NBI cystoscopy increases the visualization and detection of bladder cancer.
- TUR-BT using NBI reduces the risk of NMIBC recurrence at three months, one year, and two years significantly when compared with TUR-BT using WLI.
- At three months, NBI reduces the recurrence risk by 59.5% (NBI 6% vs WLI 14.8%).
- At one year, NBI reduces the recurrence risk by 48% (NBI 16.5% vs WLI 31.7%).
- At two years, NBI reduces the recurrence risk by 40% (NBI 17.7% vs WLI 29.5%).



Put differently, NBI Reduces the Risk of Recurrence by 48% Compared to White Light Imaging.



A network meta-analysis of therapeutic outcomes after new image technology-assisted transurethral resection for non-muscle invasive bladder cancer: 5-aminolaevulinic acid fluorescence vs hexylaminolevulinate fluorescence vs narrow band imaging⁸

Joo Yong Lee, Kang Su Cho, Dong Hyuk Kang, Hae Do Jung, Jong Kyou Kwon, Cheol Kyu Oh, Won Sik Ham and Young Deuk Choi

Background

This study included a network meta-analysis of evidence from randomized controlled trials (RCTs) to assess the therapeutic outcome of transurethral resection (TUR) in patients with non-muscle-invasive bladder cancer assisted by photodynamic diagnosis (PDD) employing 5-aminolaevulinic acid (5-ALA) or hexylaminolevulinate (HAL) or by narrow band imaging (NBI).

Methods

Relevant RCTs were identified from electronic databases. The proceedings of relevant congresses were also searched. Fifteen articles based on RCTs were included in the analysis, and the comparisons were made by qualitative and quantitative syntheses using pairwise and network meta-analyses.

Results

Seven of 15 RCTs were at moderate risk of bias for all quality criteria and two studies were classified as

having a high risk of bias. The recurrence rate of cancers resected with 5-ALA-based PDD was lower than of those resected using HAL-based PDD (odds ratio (OR) = 0.48, 95 % confidence interval (CI) [0.26–0.95]) but was not significantly different than those resected with NBI (OR = 0.53, 95 % CI [0.26–1.09]). The recurrence rate of cancers resected using HAL-based PDD versus NBI did not significantly differ (OR = 1.11, 95 % CI [0.55–2.1]). All cancers resected using 5-ALA-based PDD, HAL-based PDD, or NBI recurred at a lower rate than those resected using white light cystoscopy (WLC). No difference in progression rate was observed between cancers resected by all methods investigated.

Conclusions

The recurrence rate of some bladder cancers can be decreased by the implementation of either PDD- and NBI-assisted TUR; in real settings, clinicians should consider replacing WLC as the standard imaging technology to guide TUR.

Key Outcomes⁸

- Previous RCT and meta-analyses including this network meta-analysis have proven PDD and NBI can enhance the diagnosis of bladder lesions, guide an adequate resection, and reduce tumor recurrence.
- Both NBI and PDD are superior to WLI for reducing cancer recurrence rates after TUR-BT.
- When TUR-BT is performed using PDD or NBI, the recurrence rate of NMIBC is reduced compared to WLI by at least 35%.



Using NBI or PDD during TUR-BT Reduces Recurrence Rate Compared to WLI⁸

“ NBI was found to be a valid alternative to PDD regarding diagnosis of CIS and flat dysplasia¹⁰. ”

A prospective, nonrandomized, international multicenter study from Scandinavia analyzed the within-patient comparison of WLI, NBI, and PDD in the detection of CIS or flat dysplasia in a TURB setting.

04

Narrow-band Imaging Digital Flexible Ureteroscopy in Detection of Upper Urinary Tract Transitional-Cell Carcinoma: Initial Experience⁹

Olivier Traxer, Bogdan Geavlete, S. Gil diez de Medina, Matilde Sibony, and Saeed M. Al-Qahtani

Purpose

To characterize the appearance of normal and malignant upper urinary tract lesion appearance under narrow-band imaging (NBI) using the new URF-V digital flexible ureteroscope (DFU), and to determine if NBI, when used in conjunction with white light (WL), could improve detection of malignancy.

Patients and Methods

NBI and WL were performed in 27 patients at our university teaching hospital, 14 with known cases of upper urinary tract transitional-cell carcinoma (UUT-TCC) as follow-up (group A), and 13 patients with first-suspicion of cancer (group B). Full renal collecting system examination was performed first under WL and then under NBI by a single urologist. Biopsies were taken from all detected lesions using the biopsy forceps and sent for examination by a pathologist who was blinded to the gross description of the lesion. Pathology interpretations were then compared with the corresponding WL and NBI images. Holmium laser vaporization was performed for all apparent lesions.

Results

Subjectively, NBI significantly improved the endoscopic visualization of the tumors, providing a detailed description of their limits and vascular architecture. Objectively, five additional tumors (14.2%) in four patients, as well the extended limits of three tumors (8.5%) in three patients were detected by NBI when findings by WL imaging were considered normal.

Conclusion

This is one of the first reports regarding NBI for UUT-TCC. From this study, we recommend this technology as a valuable diagnostic method, because it considerably improves tumor detection rate by 22.7% compared with WL.

Key Outcomes⁹

- NBI has a higher diagnostic power for identifying upper urinary tract transitional-cell carcinoma (UUT-TCC) than WLI alone, objectively confirmed via histological analysis.
- NBI enables the urologist to determine the exact limits of tumors, thereby facilitating complete laser vaporization.
- From 35 detected, pathology-confirmed transitional-cell tumors NBI exclusively diagnosed five additional tumors (14.2%), and identified extended limits for another 8.5% of tumors.
- NBI improves the tumor detection rate by 23% compared with WLI.
- NBI seems to represent a valuable diagnostic technology for UUT-TCC, showing considerable improvement in tumor visual accuracy as well as in the tumor detection rate.



INCREASE DETECTION, REDUCE RECURRENCE

References

- ¹ Sylvester et al. Intravesical bacillus Calmette-Guerin reduces the risk of progression in patients with superficial bladder cancer: a meta-analysis of the published results of randomized clinical trials. J Urol 2002; 168:1964–1970.
- ² Jichlinski et al. Fluorescence cystoscopy in the management of bladder cancer: a help for the urologist! Urol. Int. 2005; 74:97–101.
- ³ Kang et al. Narrow band imaging-assisted transurethral resection reduces the recurrence risk of nonmuscle invasive bladder cancer: A systematic review and meta-analysis, Oncotarget. 2016 Nov 03.
- ⁴ Li et al. Diagnosis of narrow-band imaging in non-muscle-invasive bladder cancer: A systematic review and meta-analysis, International Journal of Urology 2013; 20:602–609.
- ⁵ Babjuk M. et al. EAU Guidelines on Non-muscle-invasive Bladder Cancer. European Association of Urology (EAU), paragraph 5.11.2, EAU Guidelines Office, March 2017.
- ⁶ Bladder cancer: diagnosis and management NICE guideline. Published 25 February 2015, nice.org.uk/guidance/ng2, retrieved on 20 February 2017.
- ⁷ American Urological Association (AUA)/ Society of Urologic Oncology (SUO) Guideline: DIAGNOSIS AND TREATMENT OF NON-MUSCLE INVASIVE BLADDER CANCER: AUA/SUO GUIDELINE, <https://www.auanet.org/common/pdf/education/clinical-guidance/Non-Muscle-Invasive-Bladder-Cancer.pdf>, retrieved on 20 February 2017.
- ⁸ Lee et al. A network meta-analysis of therapeutic outcomes after new image technology-assisted transurethral resection for nonmuscle invasive bladder cancer: 5-aminolaevulinic acid fluorescence vs hexylaminolevulinic acid fluorescence vs narrow band imaging, BMC Cancer 2015; 15: 566.
- ⁹ Traxer et al. Narrow-band Imaging Digital Flexible Ureteroscopy in Detection of Upper Urinary Tract Transitional-Cell Carcinoma: Initial Experience, J Endourol. 2011 Jan;25(1):19-23.
- ¹⁰ Drejer et al. Comparison of White Light, Photodynamic Diagnosis, and Narrow-band Imaging in Detection of Carcinoma In Situ or Flat Dysplasia at Transurethral Resection of the Bladder: the DaBlaCa-8 Study. J. Urol 2017 Apr;102:138-142.

NBI Urology Portal

Discover the clinical value of NBI in over 40 videos



www.nbi-portal.eu/uro

Specifications, design, and accessories are subject to change without any notice or obligation on the part of the manufacturer.

OLYMPUS

OLYMPUS EUROPA SE & CO. KG
Postbox 10 49 08, 20034 Hamburg, Germany
Wendenstrasse 14–18, 20097 Hamburg, Germany
Phone: +49 40 23773-0, Fax: +49 40 233765
www.olympus-europa.com

E0492498EN · 3.000 · 12/17 · OEKG · ED